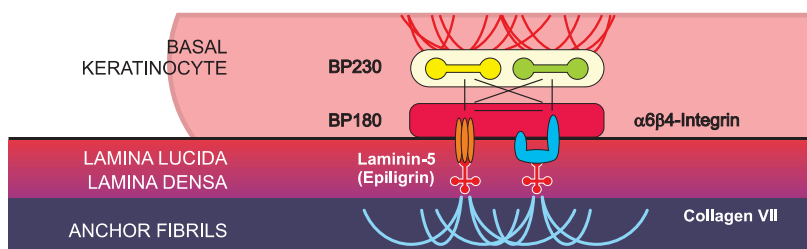


## Mucous Membrane Pemphigoid

Mucous membrane pemphigoid (MMP) is an autoimmune, chronic inflammatory, sub-epithelial blistering disease. It predominantly affects middle-aged to elderly individuals, and occurs slightly more often in females. MMP is characterized by the formation of auto-antibodies to the basement membrane zone (BMZ) antigens, particularly BP180 and BP230. The BMZ auto-antibodies activate complement that attracts neutrophils. The release of proteolytic enzymes from neutrophils causes detachment of the basal cells from the BMZ resulting in the sub-epithelial clefting at the lower lamina lucida and lamina densa levels.

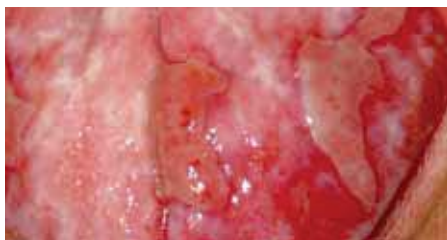- MMP can involve any mucosa with or without skin involvement. In decreasing frequency, affected tissues may include: the oral cavity, eye, nose, nasopharynx, anogenitals, skin, larynx, and esophagus. Skin involvement occurs in 20-30% of cases. Oral involvement mainly occurs as desquamative gingivitis.
- The specimen for histopathological (H&E) examination should be a punch biopsy of an early, small, intact vesicle or an erythematous area.
- This type of specimen is most likely to reveal the primary pathology, including the location of the split (intraepithelial or subepithelial).
- **Direct immunofluorescence (IF)** studies are very specific for the diagnosis of MMP. A biopsy for direct IF should be taken from normal appearing tissue immediately adjacent to a clinical lesion (perilesional site). The immunoreactants (IgG, IgA and/or C3) in the tissue are seen as linear deposits in the BMZ.



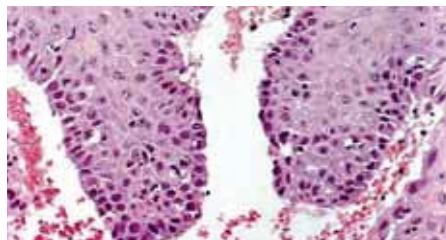
The components of the basement membrane zone (BMZ)

### Why choose Immco Diagnostics?

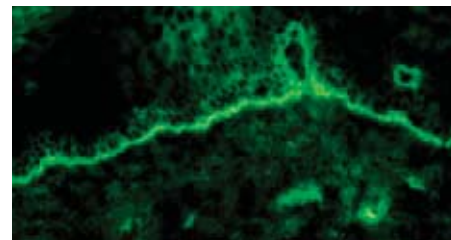
- Immco was co-founded by periodontist
- Over 40 years experience providing specialized Oral and Maxillofacial pathology biopsy services
- Board certified oral and immuno pathologist
- Accuracy and reliability
- Consultations and second opinions
- More than 100 published articles on autoimmune mediated periodontal diseases
- Lab report within 48 hours of sample receipt



Erythematous blisters on tongue



Sub-Epithelial separation



Linear immunodeposits of IgG in the BMZ



## Immco Tests

### Code Description

510 Direct Immunofluorescence – Routine panel tests for the presence of IgG, IgA, IgM, Fibrin, C3 plus C5b-9 and/or IgG4, depending on diagnosis.  
 Methodology: DIF (Direct Immunofluorescence)  
 Reference Range: Detailed interpretation accompanies report.  
 CPT Code: 88346(x6 or x7)  
 Turnaround Time: Report availability is within 48 hours from the time of specimen receipt.

## Serology Tests

See [www.immco.com](http://www.immco.com) for test details.

### Code Description

105 Intercellular (IC) and Basement Membrane Zone (BMZ) Antibodies (Dual Substrate)  
 106 Differentiation of Bullous Pemphigoid (BP) from Epidermolysis Bullosa Acquisita (EBA) on “Split Skin”  
 114 Bullous Pemphigoid 180 (BP 180) Antibody  
 115 Bullous Pemphigoid 230 (BP 230) Antibody  
 128 Pemphigoid Profile (includes 105, 106, 114, 115)

## Sample Submission

Specimen collection kits are available free of charge. Please call 1.800.537.8378 or e-mail [Stacie.WHU@immco.com](mailto:Stacie.WHU@immco.com) for supplies.

Use appropriate tube(s) as follows:

### Immunofluorescence:

Lesional biopsy .....Red tube  
 Normal biopsy .....Purple tube

H&E biopsy .....Green tube

Serology.....Orange tube

Specimen can be shipped by courier services, U.S. Postal service and overnight carriers free of charge. Results are reported within two business days of the receipt of the specimen via mail, fax and through Immco online, a HIPAA-compliant web tool at [www.immco.com](http://www.immco.com).

## Selected References

Di Zenzo G, Della Torre R, Zambruno G, Borradori L. Bullous pemphigoid: from the clinic to the bench. Clin Dermatol. 2012 Jan;30:3-16

Schmidt E, Zillikens D. Modern diagnosis of autoimmune blistering skin diseases. Autoimmun Rev 2010; 10:84-9.

Suresh L, Kumar V. Significance of IgG4 in diagnosis of mucous membrane pemphigoid. Oral Surg Oral Med Oral Path Oral Radiol Endod 2007;104:359-62.

Bagan J, Lo Muzio L, Scully C. Mucosal disease series. Number III. Mucous membrane pemphigoid. Oral Dis. 2005;11:197-218.

Chan LS, Ahmed AR, Anhalt GJ, et al. The first international consensus on mucous membrane pemphigoid: definition, diagnostic criteria, pathogenic factors, medical treatment, and prognostic indicators. Arch Dermatol. 2002;138:370-9.

For details about our products and services, please contact [laboratoryservices@immco.com](mailto:laboratoryservices@immco.com).



The total solution in autoimmunity.™

**United States**  
 Immco Diagnostics, Inc.  
 10 Earhart Drive  
 Suite 100  
 Williamsville, NY 14221  
 +1.716.691.0091  
 800.537.8378  
 +1.716.691.6955 Fax  
[laboratoryservices@immco.com](mailto:laboratoryservices@immco.com)  
[www.immco.com](http://www.immco.com)