

# Bullous Pemphigoid

Bullous pemphigoid (BP) is a rare, chronic, autoimmune, sub-epidermal, blistering disease of the skin. The cause of BP is unknown. It has an average onset of 65 years; however, a few cases of childhood onset have been reported. It is characterized by the presence of

1. Immunoglobulin IgG and complement deposits in the skin of patients and
2. The presence in the serum of immunoglobulin G (IgG) autoantibodies specific for the basement membrane zone antigens such as BP230 (BPAg1) and BP180 (BPAg2).

## Clinical Features

- It can affect any part of the skin surface, with a predilection on the flexural areas of the skin.
- It can present itself through distinct manifestations such as generalized bullous, vesicular, vegetative, generalized erythroderma, urticarial and nodular forms.

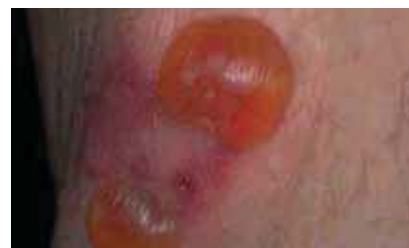## Diagnosis

Biopsy and serum analysis of the presence of autoantibodies to the basement membrane zone (BMZ) are required. Biopsy studies include H&E and direct immunofluorescence (IF). The combination of clinical, histological, and IF studies are the most reliable in diagnosis of BP.

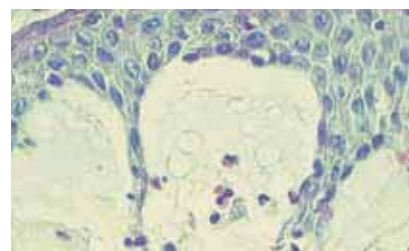
- Direct IF studies show the presence of immunoglobulins and complement in the BMZ with a linear pattern
- Serum studies detect the presence of autoantibodies to BMZ antigens by indirect IF using primate esophagus and/or split skin.
- H&E studies reveal sub-epidermal blisters.
- Direct IF studies demonstrate in vivo deposits of IgG (70-90% of patients) and complement C3 deposition (90-100% of patients) in a linear band at the BMZ.
- BP can be differentiated from EBA by localizing the site of immunodeposits on the perilesional biopsy split at the lamina lucida junction

## Why choose Immco Diagnostics?

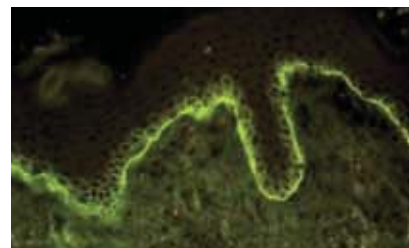
- Immco was co-founded by periodontists
- Over 40 years experience providing specialized Oral and Maxillofacial pathology biopsy services
- Board certified oral and immuno pathologists
- Accuracy and reliability
- Consultations and second opinions
- More than 100 published articles on autoimmune mediated periodontal diseases
- Lab report within 48 hours of sample receipt via fax, mail or **Immco Online**, a HIPAA-compliant web tool



**Bulla on the skin**



**H & E showing subepidermal blister containing eosinophils**



**Direct IF showing linear deposits of C3 in the BMZ**

Diagnostic Criteria	Sensitivity	Specificity
Clinical	63%	95%
Histological	27%	98%
Direct IF	90%	95%
Indirect IF	59%	99%
Clinical, Direct & Indirect IF	98%	98%

Methods of Differentiation	BP	EBA
Serum tests for BMZ antibodies on salt split skin	Roof Roof & Floor	Floor
Direct IF on normal salt split skin (may be performed on same specimen submitted for DIF)	Roof Roof & Floor	Floor
"Antigen Mapping" for Type IV collagen and Laminin on lesional biopsy	Floor	Floor

## Selected References

Fleming TE, Korman NJ: Cicatricial pemphigoid. J Am Acad Dermatol. 2000;43:571-91;

Khumalo N, Kirtschig G, Middleton P, Hollis S, Wojnarowska F, Murrell D. Interventions for bullous pemphigoid. Cochrane Database Syst Rev. 2005;(3):CD002292.

Liu Z, Diaz LA. Bullous pemphigoid: end of the century overview. J Dermatol. 2001;28:647-50.

Walsh SR, Hogg D, Mydlarski PR. Bullous pemphigoid: from bench to bedside. Drugs.2005; 65:905-26.

## Optimal Biopsy Site for Immunological Investigations

For H&E, the biopsy should be taken from the edge of a blister and for direct IF the studies biopsy should be from normal-appearing perilesional skin.

## Treatment

Topical steroids are effective, however, their use in extensive disease may be limited by side effects and practical factors. The effectiveness of the addition of plasma exchange or azathioprine to corticosteroids has not been fully established. Combination treatment with tetracycline and nicotinamide may be useful.

## Sample Submission

Specimen collection kits are available free of charge. Please call 1.800.537.8378 or e-mail [laboratoryservices@immco.com](mailto:laboratoryservices@immco.com) for supplies.

Use appropriate tube(s) as follows:

### Immunofluorescence:

Lesional biopsy .....Red tube

Normal biopsy .....Purple tube

H&E biopsy .....Green tube

Serology.....Orange tube

Specimen can be shipped by courier services, U.S. Postal service and overnight carriers free of charge. Results are reported within two business days of the receipt of the specimen via mail, fax and through Immco online, a HIPAA-compliant web tool at [www.immco.com](http://www.immco.com).



The total solution in autoimmunity.™

**For details about our products and services,  
please contact [laboratoryservices@immco.com](mailto:laboratoryservices@immco.com).**

### United States

Immco Diagnostics, Inc.  
10 Earhart Drive  
Suite 100  
Williamsville, NY 14221

+1.716.691.0091  
800.537.8378  
+1.716.691.6955 Fax  
[laboratoryservices@immco.com](mailto:laboratoryservices@immco.com)  
[www.immco.com](http://www.immco.com)