

Oral Lichen Planus

Oral lichen planus (OLP) is a chronic inflammatory disease affecting the mucous membranes of the skin and oral cavity (predominantly the buccal mucosa, tongue and gingivae, although other oral sites are occasionally involved). The pathogenesis of the condition is unknown. Current data suggest OLP is a T cell mediated autoimmune disease in which autocytotoxic CD8+ T cells trigger apoptosis of the oral epithelial cells. The lichen planus antigen is unknown. OLP affects approximately 1-2% of the general adult population and all racial groups are affected. OLP occurs in adults older than 40 years, although younger adults and children can be affected. Women are more commonly affected than males.

Clinical Features

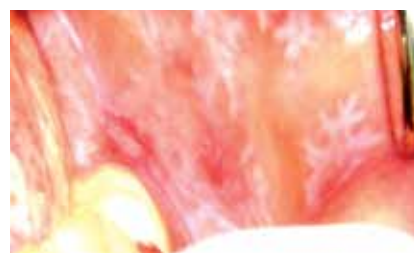- White striations (Wickham Striae) on the buccal mucosa are a common clinical presentation
- White papules, erythema (mucosal atrophy), erosions or blisters have also been noticed
- OLP lesions usually persist for many years with periods of exacerbation and quiescence

Diagnosis

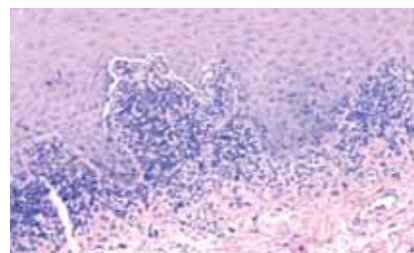
- Patient history, oral lesions and skin involvement may help Diagnose OLP
- Clinicopathological correlation including histological examination on light microscopy and direct immunofluorescence are essential in confirming diagnosis
- Biopsies should be taken from lesional tissues. If positive, a “saw-tooth” rete ridges and band of mononuclear infiltrates (T Cells) in subadjacent tissue can be observed
- Direct IF usually shows fibrillar and shaggy deposition of fibrin at the basement membrane zone (BMZ)
- Direct IF can help confirming diagnosis and distinguishing between OLP and other bullous disorders (Pemphigus Vulgaris, Mucus membrane Pemphigoid, Dermatitis Herpetiformis, and linear IgA disease)

Why choose Immco Diagnostics?

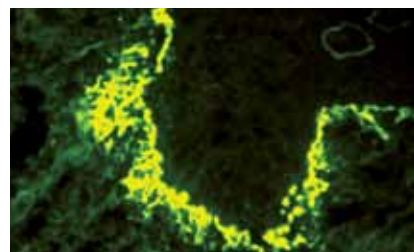
- Immco was co-founded by periodontists
- Over 40 years experience providing specialized Oral and Maxillofacial pathology biopsy services
- Board certified oral and immuno pathologists
- Accuracy and reliability
- Consultations and second opinions
- More than 100 published articles on autoimmune mediated periodontal diseases
- Lab report within 48 hours of sample receipt via fax, mail or **Immco Online**, a HIPAA-compliant web tool



White lacy striations on buccal mucosa



Biopsy showing band of lymphocytes



Shaggy and fibrillar fibrin deposits at the BMZ

Treatment

Current treatment is largely based on immunosuppression using topical corticosteroids. Recent studies with topical tacrolimus have shown promising results.

Optimal biopsy Site for direct immunofluorescence testing:

Tissue	Site	Special Considerations
Oral Mucosa	Take biopsy from the lesion	None

Immco Tests

Code Description

510 Direct Immunofluorescence

Routine panel tests for the presence of IgG, IgA, IgM, Fibrin, C3 plus C5b-9 and/or IgG4, depending on diagnosis.

CPT Code: 88346(x6 or x7)

Turnaround Time: Report availability is within 48 hours from the time of specimen receipt.

Biopsy Site Selection: Proper biopsy sites are dependent on the suspected diagnosis. Refer to Immco Diagnostics Reference Manual at www.immco.com.

511 Light Microscopy Hematoxylin and Eosin (H&E)

Reference Range: Detailed interpretation accompanies report.

CPT Code: 88321

Turnaround Time: Report availability is within 48 hours from the time of specimen receipt.

Biopsy Site Selection: Take biopsy from a lesional site in an area without ulceration. Refer to Immco Diagnostics Reference Manual at www.immco.com.

Specimen Requirements: Place the incisional or excisional biopsy specimen in the green tube provided with Immco collection kits or in a tube containing 10% neutral buffered formalin. Transport at room temperature.

Sample Stability: Stable in appropriate solution at room temperature indefinitely.

Sample Submission

Specimen collection kits are available free of charge. Please call 1.800.537.8378 or e-mail info@immco.com for supplies.

Use appropriate tube(s) as follows:

Immunofluorescence:

Lesional biopsyRed tube

Normal biopsyPurple tube

H&E biopsyGreen tube

Serology.....Orange tube

Specimen can be shipped by courier services, U.S. Postal service and overnight carriers free of charge. Results are reported within two business days of the receipt of the specimen via mail, fax and through Immco online, a HIPAA-compliant web tool at www.immco.com.

**For details about our products and services,
please contact techsupport@immco.com.**

Selected References

Eisen D, Carrozzo M, Bagan JV, Thongprasom K. Number V Oral lichen planus: clinical features and management. *Oral Dis* 2005;11:338-46.

Larozzo M, Thorpe R. Oral lichen planus: a review *Minerva Stomatol* 2009;58:519-37.

Radfar L, Wild RC, Suresh L. A comprehensive study of topical tacrolimus and clobetasol in oral lichen planus. *Oral Surg Oral Med Oral Path Oral Radiol Endod* 2008;105:187-93.

Sugerman PB, Savage NW. Oral lichen planus: causes, diagnosis and management. *Aust Dent J*. 2002;47:290-7.

Suresh L, Neiders ME. Definitive and differential diagnosis of desquamative gingivitis through direct immunofluorescence studies. *J Periodontol*. 2012; 83:1270-8.



The total solution in autoimmunity.™

United States

Immco Diagnostics, Inc.
640 Ellicott Street
Buffalo, NY 14203

+1.716.691.0091
800.537.8378
+1.716.691.6955 Fax
info@immco.com
www.immco.com